



Survey on Mammogram, Ultrasound, MRI, Spectroscopy, Biopsy for Detecting Tumor in Breast

Sivalakshmi.B¹, Mahisha sri.K.B², Swetha.P³

^{1,2,3} Research intern, KEDSGROUPS Research and Development, Coimbatore.

^{1,2,3} Department of Biomedical Engineering, SNS college of Technology, Coimbatore, Tamilnadu, India.

mailto:sivalakshmi@gmail.com¹

Abstract

Breast cancer is the most widely recognized disease among women more than 35 years. Studies have demonstrated that early recognition and appropriate therapy of breast cancer growth fundamentally increment the chance of endurance. They have additionally demonstrated that early recognition of little injuries helps anticipation and prompts a notes worthy decrease in mortality. Even though there are many diagnosing test we have taken five among them mammogram, ultrasound, MRI, spectroscopy and biopsy .X ray image of breast is known as mammogram .Specialists utilize a mammogram to search for early indications of breast disease. Ordinary mammograms are the best tests to discover breast cancer early, when an issue/ complications found by a mammogram or physical test of the breast we undergo ultrasound to identify the growth of cyst filled with liquid or a strong tumor. Breast ultrasound isn't typically done to screen the breast cancer because it might miss some early indications of cancer. A breast MRI used to screen for breast cancer growth in women thought to have a high danger of the disease. The doctor may propose MRI scan when you are said to have breast cancer and they determines how far the growth of the cancer .In vivo magnetic resonance spectroscopy (MRS) investigations of breast estimated resonances from phosphorus particles .These calculates that varieties of phospholipid digestion used for identification for diagnosing cancer and checking the feedback of treatment. A breast biopsy is a test that eliminates tissue or liquid from the suspicious zone. Examination is done with the help of separated cell using microscope to explore the existence of cancer. A biopsy is the diagnostic tool where it will discover the cancerous area. There are many papers about one equipment or comparison of two or three equipment. In this paper we have collected all five equipment specifications, working and parameters and came to the best diagnostic test among five.

Keywords: Mammogram , Ultrasound , MRI , Spectroscopy , Biopsy

1. Introduction

A cancer cell which occurs in breast means to be breast cancer. Breast cancer affect women and once in a while in men .Features of breast cancer are lump in the breast, bloody discharge from nipple and changes in shape or texture of the nipple or breast. The most significant risk factors for breast cancer are outside your ability to control like age, family history and medical history. Yet, there are few risk factors that you can control like overweight, smoking and alcohol consumption. Make sure to converse with primary care physician about all of your conceivable risk

factor for breast cancer. It is the most successive cancer among women, affecting 2.1 million women every year, and furthermore causes the best number of cancer-related passing's among women. In 2018, it is assessed that 627,000 women passed away from breast cancer – that is around 15% of all cancer deaths among women. Around 41,760 women and 500 men are await to died from breast cancer in 2019. Breast Imaging- Reporting and Data System (BI-RADS), a quality affirmation instrument initially intended for use with mammography. The framework is a synergistic

exertion of numerous wellbeing gatherings yet is distributed and reserved by the American College of Radiology (ACR). The framework is intended to normalize detailing, and is utilized by clinical experts to impart a patient's danger of creating breast disease. The record centers around are understanding reports utilized by the clinical experts, not "lay reports" that are given to patients. Early location of breast cancer growth is significant as it is connected with an expanded number of accessible treatment alternatives, expanded endurance and improved personal satisfaction. Every woman should self test there breast at home to detect the changes or issues in the breast tissue.[1-6] Numerous women feel that doing this is imperative to their well being. Anyway specialists disagree about the advantages of breast self tests in discovering breast cancer or sparing lives. Even though doing a self test is necessary but it is important to check through medical imaging techniques in order to identify accuracy of breast cancer. Ultrasound, MRI, Core biopsy, mammogram, spectroscopy, CT scan, PETS can are some of the medical imaging technique. In information of various medical imaging this review paper we have provided the techniques and their specifications. Then we provide an overview of all medical imaging methodologies includes Ultrasound and their Techniques, MRI breast cancer detection, Biopsy and their methods, Spectroscopy in cancer detection and Mammogram detection of breast cancer, breast lesion identification and breast node analyser for breast cancer detection and summarize which one of the technique have more specification, accuracy and compactability to identify breast cancer without risk, pain and a methodology that is easier to maintain .

2. System description

2.1 Ultrasound

Ultrasound is protected and easy imaging technuque. It produces photos within the body by utilizing sound waves. Ultrasound imaging is likewise called ultrasound checking or sonography. [7-10] It uses a little test called a transducer and gel set genuinely on the skin. High- recurrence sound waves travel from the test through the gel into the body. The test gathers the sounds that ricochet back. A PC utilizes those sound waves to make a picture. Ultrasound tests

don't utilize radiation (as utilized in x-beams). Since pictures are caught continuously, they can show the structure and development of the body's interior organs. They can likewise show blood coursing through veins. Ultrasound imaging is a non-invasive clinical test that assists doctors with diagnosing and treat ailments. Doppler ultrasound is a unique ultrasound procedure that assesses development of materials in the body. It permits the specialist to see and assess blood that move through conduits and veins in the body. Ultrasound imaging of the breast delivers an image of the inside structures of the breast. During a breast ultrasound assessment, the sonographer or doctor playing out the test will utilize Doppler methods to assess blood stream or absence of stream in any breast mass. Now and again, this may give extra data with regards to the reason for the mass. Ultrasound waves are reflected at the surfaces between the tissues of various thicknesses, the reflection being corresponding to the distinction in impedance. On the off chance that the distinction in thickness expanded, the extent of reflected sound is expanded, and the extent of communicated sound is proportionately diminished.[11-15]

**Table.1. Medical imaging technique –
ULTRASOUND**

Medical imaging technique – ULTRASOUND	
MODEL	SPECIFICATION
Weight of the console	5-8 kg
Dimension	35-45 cm(L);35-45 cm (H);5-10cm(D)
Battery duration	2 hours under normal use conditions
Field of view	>15 cm
Depth range selection	Multiple
Digital image storage	64GB
Cine loop	Freeze
Image grey scale	625 lines/frame 150 dB
Power supply	AC : 100 – 240 V , 50/60 hz

2.2 MRI

Breast magnetic resonance imaging (MRI) utilizes attractive fields to make a picture of the breast. Breast MRI is utilized in breast cancer screening for women at higher range than normal danger. It's additionally now and again utilized in breast disease determination and arranging. Breast MRI isn't suggested in breast cancer screening for women at normal danger. Magnetic resonance imaging (MRI) utilizes the attractive properties of certain nuclear cores. This model is a hydrogen core (a solitary proton) present in water atoms, and in this manner in all body tissues.

Table.2. Medical imaging technique –MRI

Medical imaging technique –MRI	
MODEL	SPECIFICATION
configuration	Compact short bore
synchronization	ECG/ peripheral
Imaging modes	2D single slice
FOV	1to 48 cm
Slice thickness	2D 0.7mm to 20 mm 3D 0.1mm to 5 mm
Display matrix	1028*1024
Pixel intensity	256 grey levels
Power requirement	480
Field strength	1.5T
Magnet type	uperconducting
Cooling system type	gradient

2.3 Mammogram:

Mammography is a X-beam imaging technique utilized for assessment of the female breast. It is fundamentally utilized for conclusion of breast cancer growth and in the direction of needle biopsies. The female breast is profoundly radiation-touchy. Subsequently, the radiation dose during mammography ought to be kept as low. Additionally, it is needed to accomplish preferred spatial goal over different kinds of film/screen radiographs. So as to accomplish these objectives, aX-beam tube with a little central spot size is utilized to limit the chance of mathematical haze. The film/screen tape has a solitary emulsion film and a solitary screen, and is intended to give phenomenal film/screen contact. Mammographic X-beam hardware can either be utilized with exceptional film/screen tape or as xero-radiographic units. The units expected for film/screen use have a molybdenum target X-beam

tubes with a beryllium window and a 0.03 mm molybdenum channel. Radiographs are normally taken at 28–35 kV. Xero-radiographic frameworks use X-beam tubes with tungsten targets and around 1 mm aluminium channel. Radiographs with this method are taken at 40–50 kV. Henceforth, the two sorts of mammographic units work at low pinnacle voltages. Film-based mammography has a few detriments, for example, constraints in recognition of micro calcifications and other fine structures inside the breast, and failure of frameworks in eliminating the impacts of dispersed radiation. A large number of these constraints can be viably taken out by utilizing a computerized mammography frame work in which picture securing, show and capacity are performed freely, taking into consideration enhancement of each cycle.

Table.3. Medical imaging technique – MAMMOGRAM

Medical imaging technique – MAMMOGRAM	
MODEL	SPECIFICATION
Detector technology	Amorphous selenium (aSe)
Detector size	24 cm x 30 cm (9.5“ x 12“)
Filter	Mo/Rh
Swivel range	+ 180° to – 180°
Source-detector distance	65 cm (25.6“)
Monitors	48m

2.4 Spectroscopy:

Raman spectroscopy is a delicate technique to identify early changes of sub-atomic piece and structure that happen in sores during carcinogenesis. The Raman spectra of ordinary, kind hearted and carcinogenic breast tissues were explored in vitro utilizing a close infrared (NIR) Raman arrangement of 785 nm excitation and confocal miniature reverberation Raman arrangement of 532 nm excitation. A complete number of 491 Raman spectra were procured from ordinary, kind hearted and malignant breast tissues taken from 15 patients. At the point when the 785 nm excitation was utilized, the prevailing tops in the spectra were normal for the vibrations of proteins and lipids. The contrasts between the

ordinary and destructive breast tissues were seen in both the pinnacle positions and the force proportions of the trademark Raman tops in the unearthly locale of 700–1800 cm^{-1} . With 532 nm excitation, the reverberation Raman (RR) spectra displayed a powerful example of tops inside the area of 500–4000 cm^{-1} . The forces of four unmistakable tops at 1156, 1521, 2854 and 3013 cm^{-1} identified in the spectra gathered from typical breast tissue were discovered to be more grounded in examination with those gathered from dangerous breast tissue. The twelve drastically improved trademark tops, including the upgraded amide II top at 1548 cm^{-1} in the spectra gathered from dangerous breast tissue, recognized the harmful tissue from the typical tissue. Head part investigation (PCA) joined with help vector machine (SVM) examination.

Table.4. Medical imaging technique – SPECTROSCOPY

Medical imaging technique – SPECTROSCOPY	
MODEL	SPECIFICATION
dimensions	s
spectral range	833-2,630 nm
weight	47.7 kg
Resolution	6nm at 1,250 nm.

2.5 Biopsy

At the point when different tests show that you may have breast cancer, you will presumably need to have a biopsy. Requiring a breast biopsy doesn't really mean you have cancer. Most biopsy results are not disease, but rather a biopsy is the best way to discover without a doubt. During a biopsy, a specialist will eliminate little pieces from the dubious region so they can be taken a gander at in the lab to check whether they contain cancer cells. There are several types of breast biopsies. Some are finished utilizing an empty needle, and some utilization. The types are fine needle aspiration biopsyan extremely meagre, empty needle joined to a needle is utilized to pull back a modest quantity of tissue from dubious zone. Core needle biopsy uses a greater needle to test breast changes felt by the authority or seen on mammogram, MRI,

ultrasound Surgical biopsyto Eliminate all or part of the protuberance for testing. Lymph nodebiopsy check the cancer spread in the lymph nodes under the arm.

3. Parameters

Table.5. Medical imaging technique –BIOPSY

Medical imaging technique –BIOPSY	
MODEL	SPECIFICATION
Reusable driver dimension	19.8cm*7.4cm*4.3cm
Tissue filter diameter	6.1 cm
Disposable needle specifications	35.6cm*5.1cm*3.2cm
Display monitor	18 cm
Operating system	Embedded RTOS
Energy range	20-35 kv
Anode type	tungsten
Tube current	1mA
Focal spot size	50 micrometer

The equipment which diagnose breast cancer will analysis some of the specific parameters like shape, lesion, fluid accumulation and so on to differentiate whether the cancer cell is benign or cancer tumor. Each equipment will detect different parameters according to their features and specific qualities. The cancer occurs in breast can be diagnostic using some equipments which we discussed above i.e. ultrasound, biopsy, spectroscopy, MRI and mammogram. Ultrasound can evaluate the morphology, direction, inward structure, and edges of sores from numerous planes with high goal both in transcendently greasy breast and thick, glandular structures. The overall standards for breast disease identification with ultrasound screen compassing issue, shape, edge form, sore limit, and back acoustic highlights. To classify a lesion a factor is very necessary that sisposterioracoustic features. Ultrasound can tell both benign tumors well as solid lesion. Biopsy can assess the tissue from the breast and liquid from a suspicious region. The parameters which the

spectroscopy evaluate were ex vivo sample of human breast tissue, fibrocystic change, fibro adenoma and infiltrating ductal carcinoma Magnetic resonance imaging (MRI) estimate Parameters like cancer lesions (ROI)region of interest, micro vessel density, VEGF(vascular endothelial growth factor)Mammogram evaluate breast pressure power, compacted breast thickness, mean glandular portion, and the quantity of extra perspectives required for complete breast coverage.

4. Methodology

4.1 Breast Ultrasound

Breast ultrasound is an imaging test that utilizes sound waves to take a gander at within the breasts. It can help the medical care supplier to discover breast issues. Likewise it allow medical services supplier to perceive how well blood is streaming to territories of the breasts. This test is regularly utilized when a change has been seen on a mammogram or when a change is not felt, yet doesn't appear on amammogram. Prior to the ultrasound, the PCP will look at the breast. By that time a reasonable gel was applied to the breast. This conductive gel enables the sound waves to go through your skin, at that point a wand-like gadget moved and brought a transducer over the breast. The transducer sends and gets high- recurrence sound waves. As the waves bob off the inward structures of a breast, the transducer records alter sin their pitch and course. This makes a constant chronicle of within breast PC screen. On the off chance that they discover something dubious, and the picture was recorded .A wand like gadget brought a transducer over the skin to make the pictures of your breasts. The transducer conveys sound waves that ricochet off the breast tissue. The sound waves are too sharp for you to hear. The transducer at that point gets the bobbed sound waves.

4.2 Breast biopsy

A breast biopsy is a method to eliminate a little example of breast tissue for lab testing. A breast biopsy gives an example of tissue that specialists use to distinguish and analyze variations from the norm in the cells that make up breast bumps, other surprising breast changes, or dubious or concerning discoveries on a mammogram or ultrasound.

4.2.1 Biopsy in Fine-needle aspiration

This is the least complex sort of breast biopsy and might be utilized to assess a knot that can be felt during a clinical breast test. The needle is joined to a needle that can gather an example of cells or liquid from the knot. Fine-needle desire is a speedy method to recognize a liquid filled pimple and a strong mass and, perhaps, to maintain a strategic distance from a more intrusive biopsy technique. Assuming, in any case, the mass is strong, a tissue test will be gotten.

4.2.2 Biopsy in Core needle

This kind of breast biopsy might be utilized to survey a breast irregularity that is noticeable on a mammogram or ultrasound or the primary care physician feels (touches) during a clinical breast test. A radiologist or specialist utilizes a dainty, empty needle to eliminate tissue tests from the breast mass, frequently utilizing ultrasound direction.

4.2.3 Stereotactic biopsy

This sort of biopsy utilizes mammograms to pinpoint the area of dubious territories inside the breast. The radiologist makes a little entry point around 1/4-inch long (around 6 millimetres) into the breast. The individual in question at that point embeds either a needle or a vacuum-fuelled test and eliminates a few examples of tissue. The examples are shipped off a lab for investigation

4.2.4 Biopsy in Ultrasound-guided core needle

This kind of centre needle biopsy includes ultrasound an imaging strategy that utilizes high-recurrence sound waves to deliver exact pictures of structures inside the body. The radiologist finds the mass inside the breast makes a little entry point to embed the needle and takes a few centre examples of tissue to be shipped off a lab for examination.

4.2.5 MRI-guided core needle biopsy

This kind of centre needle biopsy is done undrdirection of a MRI an imaging strategy that catches numerous cross-sectional pictures of the breast and joins them, utilizing a pc, to create definite 3-d pictures. The MRI machine gives pictures that help decide the specific area for the biopsy. A little entry point around 1/4-inch long (around 6 millimetres) is made to permit the centre needle to be embedded. A few examples of tissue are taken and shipped off a lab for investigation.

4.2.6 Surgical biopsy

During a careful biopsy, a part of the breast mass is eliminated for assessment (incision biopsy) or the

whole breast mass might be taken out (excisional biopsy, wide neighborhood extraction or lumpectomy). A careful biopsy is normally done in a working room utilizing sedation given through a vein in grasp or arm (intravenously) and a Neighborhood sedative to numb. During medical procedure, the specialist will endeavour to eliminate the whole breast mass alongside the wire. To help guarantee that the whole mass has been eliminated, the tissue is shipped off the emergency clinic lab to affirm whether breast disease has been distinguished and assuming this is the case, the (negative edges) of the mass are assessed to decide if cancer cells are available in the edges (positive edges).

4.3 Mammogram:

A Mammogram is a low-divide x-bar that grants masters called radiologists to look for changes in breast issue. Mammogram can regularly discover or identify breast cancer early, when it's little and even before a protuberance can be felt. This is the point at which it's most straightforward to treat.

4.3.1. Screening mammograms:

A screening mammogram is utilized to search for indications of breast cancer growth in ladies who don't have any breast manifestations or issues. X-beam photos of each breast are taken, regularly from 2 unique points.

4.3.2. Symptomatic mammograms:

Mammograms can likewise be utilized to take a gander at a lady's breast on the off chance that she has breast indications or if a change is seen on a screening mammogram. At the point when utilized along these lines, they are called demonstrative mammograms. They may incorporate additional perspectives (pictures) of the breast that aren't important for screening mammograms. Now and then indicative mammograms are utilized to screen ladies who were treated for breast cancer growth previously. Mammograms can regularly show irregular regions in the breast. They can't demonstrate that an unusual territory is cancer growth, however they can assist wellbeing with caring suppliers choose whether additionally testing is required. Mammogram show two fundamentals i.e. Calcifications' and masses.

4.4 Spectroscopy:

Raman spectroscopy, a promising method in breast disease determination. This optical procedure can possibly tackle the issues. To begins with; ramanspectra can give data of particles like lipids, DNA, and proteins to recognize destructive sores

from noncancerous sores. atomic changes may likewise demonstrate the instrument of cancer advancement. Because of its ongoing qualities, ramanspectroscopy is a ground-breaking intra operative demonstrative procedure. besides, when joined with a nanotag, ramanspectroscopy can uncover whether cancer is touchy or impervious to an anticancer medication.

4.4.1 Raman Spectroscopic Measurement

Information were obtained by utilizing a Raman framework. The excitation spot is $\approx 100 \mu$ min measurement, and light dispersion in the tissue brings about an examined volume of $\approx 1 \text{ mm}^3$. Raman spectra were obtained with a 10-to 30-s mix time, contingent upon signal force, and a phantom goal of 8 cm^{-1} . The normal laser excitation power fluctuated somewhere in the range of 100 and 150 mW. The fluencies utilized in this examination are ok for clinical examinations. No tissue harm was watched, either horribly or upon histological audit. Information preparing was performed as portrayed model fitting was performed by utilizing a direct blend of premise spectra with a non-negativity limitation. The commitment of every premise range, gotten from the model portrayed above, to the breast tissue examples was obtained by normalizing the fit coefficients (barring water, since it is applied exogenously) with the end goal that they aggregate to one. To Decide the blunder in our fit coefficients, we utilized a χ^2 examination χ^2 investigation is a notable strategy for ascertaining the decency of a fit just as the blunder related with model fitting. The mistake bars (one SD), are created from this investigation. The Raman spectra in each analytic gathering have diverse sign to-commotion proportions; hence, mean blunders are accounted for every pathology.

4.5 Breast MRI

Breast MRI utilizes radio waves and solid magnets to make point by point photos of within the breast.

To help decide the degree of breast cancer growth: Breast MRI is now and then utilized in ladies who as of now have been determined to have breast disease, to help measure the size of the cancer, search for different tumors in the breast, and to check for tumors in the contrary breast. Be that as it may, few out of every odd lady who has been determined to have breast cancer growth need breast MRI.

To screen for breast cancer growth: For specific ladies at high danger for breast disease ,a screening MRI is suggested alongside a yearly mammogram. X-ray isn't suggested as a screening test without anyone else on the grounds that it can miss a few diseases that a mammogram would discover. Despite the fact that MRI can discover a few malignancies not seen on a mammogram, it's additionally bound to discover things that turn out not to be disease (called a false positive).This can bring about a lady getting tests and additionally biopsies that end up not being required. This is the reason MRI isn't suggested as a screening test for ladies at normal danger of breast cancer.

5. Result:

MRI, Mammogram, ultrasound, spectroscopy and biopsy yield respective sensitivity values of 100%, 49%, 82%, 97% and 77%, while the respective specificity values for these imaging equipments were 50%, 89%, 84%, 60%, and 76%. Sensitivity is the extent of genuine positive that are effectively recognized by a symptomatic test. Sensitivity is regularly used to show or assess the precision of a test for accurately precluding the presence of some condition or infection site . By comparing all those five diagnostic equipment sensitivity and specificity of MRI and ultrasound are considerable. The major reason for this wide specificity and sensitivity range is that both benign and malignant lesions enhance. MRI, Mammogram, ultrasound, spectroscopy and biopsy achieved positive prediction value (PPV) of 83.3%, 53%, 60%, 70% and 90% respectively.

PPV is a prospect that subjects with a positive screening test really have the infection. After the analysis of PPV of mammogram and ultrasound are low in range .ultrasound value is less than the mammogram.MRI, Mammogram, ultrasound, spectroscopy and biopsy surveyed negative prediction values (NPP) are 100%, 88%, 94%, 95% and 85% respectively. NPV is a prospect that subjects with a negative screening test really don't have the infection. MRI, ultrasound and spectroscopy have more NPV values because the best apparatuses around for discovering breast tumours, even those filling in dence tissue which is famously difficult to picture. The accuracy of MRI, Mammogram, ultrasound, spectroscopy and biopsy were 85%, 81%, 84%, 65% and 81% respectively. Regarding the accuracy level of all

those five equipments MRI and ultrasound are high in value. In overall analysis MRI and ultrasound are the only definitive diagnostic tool to detect breast cancer in better and best way.

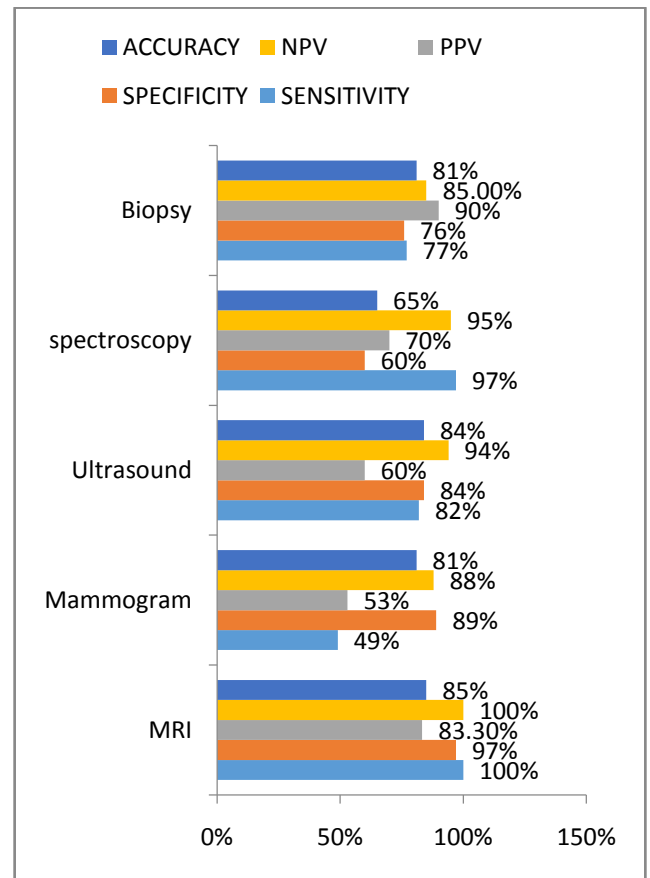


Fig.1 .Diagnosis range

Conclusion:

In this paper we discussed the specification, working and parameters of five equipments which is utilized to diagnose breast cancer. The five equipment's are MRI, spectroscopy, ultrasound, mammogram and biopsy. Comparing the five equipment's MRI and ultrasound detect the breast cancer cell with more accuracy. MRI is so sensitive when compared with mammogram, ongoing examination MRI can discovered some little breast sores that are missed by mammogram. A breast ultrasound is an imaging procedure usually used to screen for tumors and other breast abnormalities. The ultrasound utilizes high-frequency sound waves to give accurate pictures of the breasts. Dissimilar to X-beams and CT scan, ultrasounds don't utilize radiation and are said to be safe for pregnant women and for mom who is lactating for child. In future, we are intended to

join the boundaries and particular of MRI and ultrasound as a solitary hardware to give definite accuracy of breast breast cell whether it is harmful or kind tumor to give further helpful therapy for the breast cancer growth patients.

Acknowledgement

I wish to thank Mr. Nirsandh .G and other mentors of **KEDS GROUPS Research and Development** for their constant support and effective training on writing this paper.

References

Conference proceedings

- [1].Priya Hankre , PhD , Dr. Alice N. Cheeran “ An automated portable and non invasive approach for breast tumor findings using 2D Electrical Impedance Tomography in Early stage ,” 2020 IEEE
- [2]. ParvelKral ,LadislavLenc “ LBP features for breast cancer detection ,” 2016 IEEE .
- [3].MamathaSaiYarabarla , Lakshmi Kavya Ravi , A. Sivasangari “ Breast cancer prediction via machine learning ,” 2019 IEEE.
- [4].meriemamrane ,salihaoukid , ikramgagaoua and toлгаensari “Breast cancer classification using machine learning ,” 2018 IEEE.
- [5].R.Sangeetha ,K.Srikantamurthy “ A novel approach for detection of breast cancer at an early stage using digital image processing techniques ,” 2017 IEEE

Journal proceedings

- [6]. Cody J. Clarke , Ephraim F.Zegeye “ An affordable and portable palpable system for sensing breast tissue abnormalities , “ 2020, Montview liberty university journal of undergraduate research
- [7].brianL.SpraguePhD ,R.Yatescoley PhD and Karla Kerlikowske “ assessment of radiologist performance in breast cancer screening using digital tomosynthesisvs digital mammography ,” 2020 JAMA network open
- [8].stamatiaV.Destounis ,Renee Morgan and Andrea arieno “ Screening for dense breasts : digital breast tomosynthesis ,” 2015 American journal of roentgenology
- [9].XuanAhnPhi , Alberto Tagliafico , Geertruida H.de Bock “ Digital breast tomosynthesis for breast cancer screening and diagnosis in women with dense breast – a systematic review and meta analysis ,” 2018 BMC cancer.

- [10].richaagarwal ,oliverdiaz , moihoon yap , Xavier Llado , Robert marti “ Deep learning for mass detection in full field digital mammogram ,” 2020 computers in biology and medicine
- [11].abdullah C.S Talari ,ShazzaRehman and ihtesham U rehman “ Advancing cancer diagnostics with artificial intelligence and spectroscopy : identifying chemical challenges associated with breast cancer ,” 2020 expert review of molecular diagnostics.
- [12].Tayler M.Schwartz , Stephen L.Hillis , RadhikaSridharan , Olga Lukyyanchenko , William Geiser , Gary J.Whitman ,Wei Wei and Tamara miner haygood “ Interpretation time for screening mammography as a function of computer aided detection marks ,” 2020 Journal sof medical imaging
- [13].E.M.Quinn .E.Dunne , F.Flanagan , S.Mahon , M.stokes , M.J.Barry , M.kell , S.M.Walsh “ Radial scars and complex sclerosing lesions on core needle biopsy of the breast : upgrade rates and long term outcomes ,” 2020 Breast cancer research and treatment.
- [14].Rakhashanda Layee qurrahman , Yana pucket , ZainaHabrawi , Sybil Crawford “ A decade of intraoperative ultrasound guided breast conservation for margin negative resection – radioactive , magnetic and infrared Oh My ..” 2020 The American journal of surgery
- [15].W.B.G .Sanderink , L.J.A . Strobbe , P.Bult ,M.S.Schoolz-vries ,S.Lardenoije , D.J.Venderink , I.Se chopoulos , N.Karssemeijer , M.Vreuls and R.M .Mann “ Minimally invasive breast cancer excision using the breast lesion excision system under ultrasound guidance ,” 2020 Breast cancer research and treatment.